

Implantation and Prosthetic Rehabilitation Following Traumatic Dental Avulsion in a Dog

Marija Jovanovic^{1*}

Marko Ristic²

Kosta Todorovic³

Simona Stojanovic³

Milan Spasic³

Goran Jovanovic³

Rodoljub Jovanovic⁴

¹Department of Prosthetic Dentistry, Faculty of Medicine, University of Nis, Nis, Serbia

²Department of Veterinary Medicine, Faculty of Agriculture Krusevac, University of Nis, Krusevac, Serbia

³Department of Oral Surgery, Faculty of Medicine, University of Nis, Nis, Serbia

⁴Student of doctoral academic studies – dental sciences, Faculty of Medicine, University of Nis, Nis, Serbia

*Corresponding author:

Marija Jovanovic

Department of Prosthetic Dentistry, Faculty of Medicine, University of Nis,

81 Dr. Zoran Đinđić Blvd. 18108 Niš, Serbia

E-mail: jovanovicgmarija94@gmail.com

KEY WORDS: Dental implant, prosthetic rehabilitation, dental avulsion, dog

ABSTRACT

Avulsion is a very rare traumatic injury in dogs which involves complete displacement of a tooth from the alveolar socket. This paper describes the implantation and prosthetic rehabilitation of a complete displaced left maxillary lateral incisor. A 2-stage dental implant placement was applied. The primary and secondary implant stability were measured using resonance frequency analysis. Six months later and following a successful osseointegration, a metal ceramic crown was made and cemented. The dog's owner

should be introduced to the treatment and possible complications as well as the dog's future diet, teeth care and regular checkups of periodontal tissues.

INTRODUCTION

Traumatic teeth injuries in dogs are a consequence of biting hard objects, traffic accidents, falls from great heights, fighting with other animals, etc. They mostly involve fracture of the tooth crown and root whereas luxation and particularly avulsion of teeth are less common.

Avulsion or traumatic complete displacement of teeth is a form of injury where,

due to a physical trauma to the jaw, the whole tooth is complete displaced from the alveolar socket. The injury may be joined with damage to the surrounding soft and bone tissue. The loss of tooth is diagnosed by an x-ray which clearly shows a complete lack of tooth and an empty alveolar socket. With smaller amount of time from avulsion, a reimplantation may be attempted but specific conditions need to be met.¹ Nowadays, immediate implantation is a more acceptable solution on condition that there is no infection and no significant damage of the surrounding tissue. However, a delayed implantation is indicated in cases where the dog is brought to the vet after a longer period of time from the avulsion, i.e. several weeks or months later. Prosthetic rehabilitation is done after implant osseointegration.

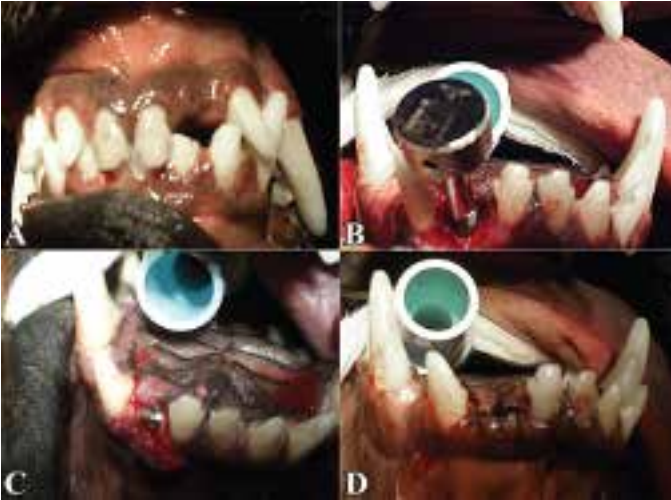Implantation is a completely predictable method and it is very successfully performed in human dentistry today. From the ethical standpoint, there are certain contradictions concerning the justification for conducting such a procedure in veterinary dentistry. It is believed that a loss of a tooth will not create major problems to the dog during mastication and the implantation will not significantly improve the dog's quality of life. The implantation unnecessarily exposes the dog to the risk of multiple anesthesia, discomfort and fear, possible complications during and after implantation intervention as well as possible development of periimplantitis due to inadequate oral hygiene and different diet compared to people.² On the other hand, modern veterinary medicine should follow modern medicine and dentistry. Numerous dental procedures which were previously available only to people are today successfully performed on animals as well. This primarily refers to periodontal, endodontic, surgical and restorative dental procedures. General anesthesia in dogs is relatively safe and it is commonly used in the majority of dental interventions. Similar to other dental procedures, implantation will with time find its place and will be accepted by the veterinary medicine as a possible solution in certain situations.³

Inadequate pressure directly on the bone during mastication and a lacking tooth gradually lead to bone loss which becomes more prominent during the dog's life span if the animal suffers tooth loss early in life. Implantation can preserve bone mass because it prevents or delays bone loss. One study reported a minimal vertical loss of crestal bone one year after implantation, three years after implantation they even observed an increase in the vertical level of the crestal bone and five years later the vertical level of the crestal bone remained stable with high implant survival rate of 97.76%⁴ The loss of teeth ruins the dog's esthetic appearance, which in some cases may cause problems to the owner. This is particularly the case with teeth in the frontal region. Alveolar collapse can sometimes lead to lip bite with ulceration on the buccal mucosa.

Implantation is irregularly performed in veterinary medicine today. Experimental studies with dogs show a high degree of osseointegration. Using histomorphometric analysis, 74.4% - 83.7% of bone-implant contacts were registered, depending on the type of implant placed in the premolar regions of the dogs' mandibula.⁵ However, there is no sufficient evidence about duration of the used implants functionally loaded with prosthetic restorations. The American authors stated that a three-year monitoring of the two implants and two bridges with four metal ceramic crowns in the frontal region of a dog's lower jaw showed no radiographic and periodontal changes⁶. On the other hand, inflammatory periodontal changes and vertical loss of bone tissue were found seventeen months after implant placement in the area of the first mandibular molar in a dog⁷. Time will tell how long implant can last and whether their application in dogs serves any purpose.

When deciding on the implant prosthetic procedure, the vet should inform the dog's owner about all other treatment options without insisting on implantation. However, when implantation is the only possible solution, as in our case, the dog's owner should

Figure 1. Surgical procedure: (A) lack of tooth #202 with normal appearance of oral cavity mucosa, (B) placement of implant into implant bed, (C) implant with healing cap, (D) surgical wound after suturing.



be aware of possible complications that can impact the lifespan of the implant. Considering that very hard food can damage the implant and the future prosthetic restoration, the dog's diet needs to be adjusted to the new situation.

CASE HISTORY

The paper describes the case of the maxillary left second incisor (202) avulsion in a male 8-year-old rottweiler weighing 40 kg, brought to the Veterinary Clinic for Cats and Dogs. The owner brought the dog to the vet 7 months after the avulsion took place and she had not previously sought veterinary care service concerning the problem. The clinical examination determined that the dog did not show signs of the disease.

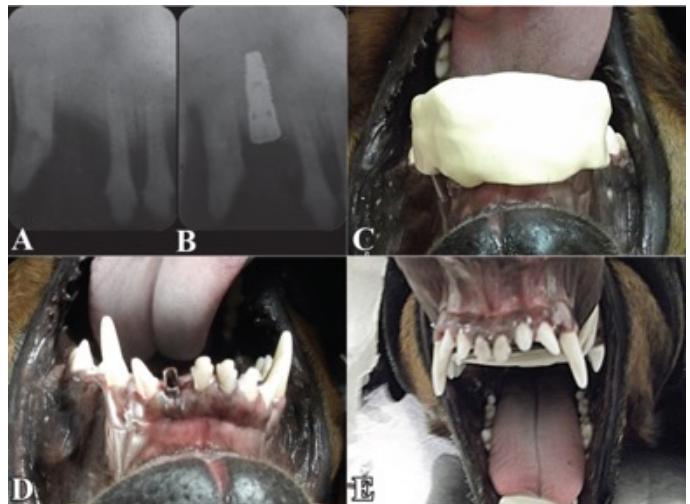
Intraoral examination showed a lack of the mentioned tooth. Soft tissues were completely healed

whereas the keratinizing gingiva preserved its morphological characteristics (Figure 1 A). The x-ray showed an empty alveolar socket completely filled with a newly formed bone tissue with no loss of bone mass compared to other teeth, and with horizontal resorption of the alveolar ridge matching the dog's age (Figure 2 A).

The owner was informed about implant-prosthetic and anesthesiology procedures as well as with possible complications and pain management during and after the intervention. After receiving information concerning the length of the

procedure, possible surgical and postsurgical complications, dog's diet, oral care following implantation, as well as all other details of implant-prosthetic rehabilitation, the owner gave written consent, which fulfilled the ethical and professional standards for animal welfare.

Figure 2. Retroalveolar image of (A) the frontal maxilla seven months after avulsion and (B) implant immediately after surgery. Prosthetic procedure: (C) impression taking, (D) fixed abutment, (E) cemented metal ceramic crown tooth #202.



Implant-prosthetic treatment was conducted in two stages. The first stage included implant placement whereas the second stage, six months later and after osseointegration, included a metal ceramic prosthetic restoration. During both stages, the implant stability was measured using Resonance Frequency Analysis device – RFA (Osstell Beacon, V&H, Brusaporto, Bergamo, Italy). First, a transducer (Smartpeg) was fixated on the implant and then the device was activated to create a magnetic impulse which was sent through a probe to the transducer 2 mm away. Stability was measured on two sides of the implant (buccal and mesial or distal). The obtained value was shown on the device display and it was expressed in ISQ (implant stability quotient) units, which were presented on a 1 to 100 scale.

Anesthesia

Before anesthesia and surgical intervention, the dog underwent a detailed clinical and laboratory (blood work) examination in order to assess his general health. General intravenous anesthesia was administered. The dog was anesthetized three times - first, when the implant was placed; second, when the implant was uncovered and tooth impressions were taken and the third anesthesia was administered when the metal ceramic crown was cemented. The dog was not anesthetized for x-ray or when the sutures were removed (on the seventh day). The anesthesia was composed of 10% ketamine hydrochloride (10 mg/kg), premedication with acepromazine (0.03 ml/kg), midazolam (0.03 mg/kg) and atropine (0.02 mg/kg). Following premedication, to insure the safety of the surgical intervention, the dog was intubated, laid on his back and his extremities and upper and lower jaws were fixated with a bandage. Local infiltration plexus anesthesia, administered in the operative area for hemostatic effect, was composed of 2% lidocaine with 1 : 100.000 adrenaline in a 2 ml dose.

Surgical procedure

After full-thickness mucoperiosteal flap elevation, we approached the crestal alveolar

bone which was wide enough for implant placement. The implant bed was made using standard protocol, with increasing drill diameters and abundant cooling with physiological solution. Using a tap, threads were made in the coronary bone area. A 3.5 x 11 mm implant (C-Tech, Bologna, Italy) was manually placed (Figure 1 B) and a torque wrench provided a 40 Ncm insertion torque. RFA device determined the primary implant stability of 74 ISQ. Healing cap was placed (Figure 1 C), the flap was returned to its position and sutured with interrupted stitches so that the implant was completely covered by mucoperiosteal flap without any possibility for interacting with the oral cavity (Figure 1 D). X-ray immediately after the intervention showed the position of the implant with regard to the bone and the adjacent teeth (Figure 2 B).

Following the surgical procedure, the patient was administered a five-day antibiotic therapy (amoxicillin and clavulanic acid) and probiotic. The antibiotic was administered subcutaneously on the day of the surgery and one day after the surgery (1 ml / 20 kg) and the remaining 5 days the antibiotics were administered orally (12.5 mg/kg) two times a day.

Prosthetic procedure

Six months following the surgical procedure, the implant was uncovered with a scalpel, making a minimal cut in the gingiva. On this occasion, it was determined that the implant was stable and immovable. The healing cap was removed and the RFA device was used to measure the secondary implant stability which was 75 ISQ. Next, the impression coping was placed and with additional silicone impression material (Optosil/Xantopren, Kulzer GmgH, Hanua, Germany) and manually mixing the mass and the catalyst, impression of the upper jaw and dental antagonists of the lower jaw was taken, determining the inter-jaw ratio in central occlusion in wax (Figure 2 C). Based on the impression, working models were made in the lab with implant analogue, which were placed in an articulator and based on

which a metal ceramic crown was made. Seven days later, a laboratory processed abutment was placed (Figure 2 D) with a 30 Ncm torque, and a metal ceramic crown was cemented on it using a composite cement (DTK-Kleber, Bredent & Co., Senden, Germany) (Figure 2 E). Finally, the occlusion of the metal ceramic crown was examined in order to determine a possible premature contact with opposite teeth.

DISCUSSION

Traumatic tooth avulsion in dogs is very rare. It is caused by a strong force which acts on the tooth at a certain angle so that the tooth and/or bone do not crack but the tooth is completely dislodged from the alveolar socket. In our case, the dislodged tooth was in the front, which presented a problem to the dog's owner because the dog's esthetic appearance was ruined. In such a situation, two options are available - take no action or place an implant with a prosthetic restoration.

The implantation can be done in one stage, where the implant is protuberant and interacts with the oral cavity, or in two stages, where the implant is first covered with mucoperiosteal flap and then, after a certain period of time and osseointegration, it is surgically uncovered and put into function. The two-stage treatment prevents too early implant loading, spread of infection and ingrowth of epithelial tissue into the peri-implant space.⁸ We decided to use the two-stage treatment because it protects the implant from unwanted and harmful effects from the outside environment and it prevents the damage of the implant during mastication and other activities of the dog. Dogs, contrary to humans, cannot apply the required care for implants during mastication. It is very important that the mucoperiosteal flap is mostly composed of keratinizing mucosa, the lack of which can present a problem during flap adaptation and primary closure. The amount of bone tissue at the osteotomy and implant bed site was sufficient and of good quality for achieving primary stability so that there was no need

for guided bone regeneration with resorbable membranes, autogenous bone or bone substitutes. This shortened the time of the overall implantation procedure as well as the length of time the dog was exposed to general anesthesia.

Primary stability refers to mechanical stability of the implant in the bone and it is important for good osseointegration.⁹ With time, it develops into secondary or biological stability, which is the result of the regeneration and remodeling of the implant-bone connection. The primary implant stability reduces in the first three weeks after implementation and then it gradually increases.¹⁰ The RFA method is a non-invasive and acceptable way to monitor the primary and secondary implant stability. The recommended values of the stability coefficient range from 70 ISQ and up to 100. In our case, the secondary stability coefficient (75 ISQ) was higher than the primary stability coefficient (74 ISQ), which points to a good osseointegration of the implant. Early loss of implant is a result of bad osseointegration. Such implants show continuous reduction of stability until complete failure.¹¹ Considering the high level of biological stability and good osseointegration of the implant, we can expect its longevity.

Prosthetic restoration was cemented using adhesive composite cement which creates an extremely strong connection between two metal surfaces and as such it is recommended for abutment and metal-ceramic crown attachment.¹² The literature also describes the application of a similar cement for attaching full metal crown and the maxillary fourth premolar in a dog, where mastication forces are much stronger than with incisors, as presented in this case.¹³

Dogs' diet commonly includes hard, raw and slightly processed food. They often chew on bones but also different objects during play and these can damage their teeth. The front teeth are used for cutting food whereas lateral teeth are used for chewing. Such trauma can cause loss of implant. In our case, an extenuating circumstance is

the fact that it was the front tooth where the functional load of the implant is much smaller compared to lateral teeth, especially if the owner takes care of the dog's diet. One experimental study stated that even excessive eight-month occlusal loading of the implant in the area of lateral teeth did not cause loss of bone or impact the osseointegration of the implant¹⁴. Similar data were obtained by other authors who stated that three years following the placement of 30 implants at the site of extracted maxillary canines in cats, there was no disruption in osseointegration even though the jaws were under full functional load via prosthetic zirconia crowns.¹⁵

It is believed that periodontal disease and periimplantitis are the most common causes of subsequent loss of implants¹⁶. Implant lifespan is significantly impacted by dental care and regular checkups. Considering the location of the implant in our case and easy access to the frontal region, the dog's owner will have no problem maintaining appropriate dental care and hygiene of her pet. Periodical checkups and maintenance of periodontal tissues is understood.

Although implantation is not common enough in veterinary practice today for its use to become more massive as is the case with humans, we believe that in some circumstances it can be applied as the only possible solution. Ethical dilemmas in veterinary medicine, compared to human medicine, have always existed and will continue to exist.¹⁷ However, people have become aware of the importance of their pets' oral health and its impact on the pets' lifespan, in addition to better diet, so that the veterinary medicine is justifiably expected and required to provide the best healthcare of pets.¹⁸

Implantation after traumatic avulsion of teeth in dogs is a possible and acceptable solution in cases where front teeth are involved. Advantage is given to two-stage approach to implant placement. The forces of mastication, which are smaller on the front teeth compared to lateral teeth, and

good occlusion of the prosthetic restoration are very significant for implant lifespan. The dog's owner needs to be introduced with the complete treatment and possible complications as well as the future diet of the dog, dental care and regular checkups of the periodontal tissues.

REFERENCES

1. Spodnick GJ. Replantation of a maxillary canine tooth after traumatic avulsion in a dog. *J Vet Dent*. 1992; 9 (4): 4-7. doi: 10.1177/089875649200900403
2. Tannenbaum J, Arzi B, Reiter AM, Tzt D, Peralta S, Snyder CJ, Lommer MJ, Harvey CE, Soukup JW, Verstraete FJ. The case against the use of dental implants in dogs and cats. *J Am Vet Med Assoc*. 2013; 243 (12): 1680-1685. doi: 10.2460/javma.243.12.1680
3. Mele RE, Caiafa A, Kurtzman GM, Mahesh L. Endosseous implant/crown survival in a companion animal: a case study. *Int J Oral Implantol Clin Res*. 2015; 6 (1): 26-34. doi: 10.5005/jp-journals-10012-1132
4. Bruschi GB, Capparè P, Bravi F, Grande N, Gherlone E, Gastaldi G, Crespi R. Radiographic evaluation of crestal bone level in split-crest and immediate implant placement: minimum 5-year follow-up. *Int J Oral Maxillofac Implants*, 2017; 32 (1): 114-120. doi: 10.11607/jomi.4203
5. Chung SH, Heo SJ, Koak JY, Kim SK, Lee JB, Han JS, Han CH, Rhyu IC, Lee SJ. Effects of implant geometry and surface treatment on osseointegration after functional loading: a dog study. *J Oral Rehabil*. 2008; 35 (3): 229-236. doi: 10.1111/j.1365-2842.2006.01653.x
6. Mele RE, Caiafa A, Kurtzman GM. Dental implants and incisor bridge placement in a dog. *J Vet Dent*. 2016; 33 (4): 249-258. doi: 10.1177/0898756416689348
7. Ruhnau J, Olsen T, Greven V, Nielsen K, Herbild K. Dental implant of the mandibular first molar tooth in a dog. *J Vet Dent*. 2003; 20 (2): 84-90. doi: 10.1177/089875640302000203
8. Fritz ME. Two-stage implant systems. *Adv Dent Res*. 1999; 13: 162-169. doi: 10.1177/08959374990130010601
9. Brånemark PI, Adell R, Albrektsson T, Lekholm U, Lindstrom J, Rockler B. An experimental and clinical study of osseointegrated implants penetrating the nasal cavity and maxillary sinus. *J Oral Maxillofacial Surg*. 1984; 42 (8): 497-505. doi: 10.1016/0278-2391(84)90008-9
10. Kim SJ, Kim MR, Rim JS, Chung SM, Chin SW. Comparison of implant stability after different implant surface treatments in dog bone. *J Appl Oral Sci*. 2010; 18 (4): 415-420. doi: 10.1590/s1678-77572010000400016
11. Glauser R, Sennerby L, Meredith N, Ree A, Lundgren A, Gottlow J, Hämmerle CHF. Resonance frequency analysis of implants subjected to immediate

- or early functional occlusal loading. Successful vs. failing implants. *Clin Oral Implants Res.* 2004; 15: 428-434. doi: 10.1111/j.1600-0501.2004.01036.x
12. Musani S, Musani I, Dugal R, Habbu N, Madan-shetty P, Virani D. An in vitro comparative evaluation of micro tensile bond strength of two metal bonding resin cements bonded to cobalt chromium alloy. *J Int Oral Health.* 2013; 5 (5): 73-78
 13. Wingo K. Cementation of full coverage metal crowns in dogs. *J Vet Dent.* 2018; 35 (1): 46-53. doi: 10.1177/0898756418757247
 14. Heitz-Mayfield LJ, Schmid B, Weigel C, Gerber S, Bosshardt DD, Jönsson J, Lang NP, Jönsson J. Does excessive occlusal load affect osseointegration? An experimental study in the dog. *Clin Oral Implants Res.* 2004; 15 (3): 259-268. doi: 10.1111/j.1600-0501.2004.01019.x
 15. Mele RE, Kurtzman GM. Feline dental implants: new paradigm shift in maxillary alveolar osteitis treatment planning with osseodensification. *J Osseointegr.* 2019; 11 (3): 485-492. doi: 10.23805/JO.2019.11.03.04
 16. Renvert S, Persson GR, Pirih FQ, Camargo PM. Peri-implant health, peri-implant mucositis, and peri-implantitis: case definitions and diagnostic considerations. *J Periodontol.* 2018; 89 (1): 304-312. doi: 10.1002/JPER.17-0588
 17. Hale FA. Orthodontic correction for breeding and show dogs - an ethical dilemma. *J Vet Dent.* 1991; 8 (3): 14. doi: 10.1177/089875649100800306
 18. Colmery B. The Gold Standard of Veterinary Oral Health Care. *Vet Clin North Am Small Animal Practice.* 2005; 35 (4): 781-787. doi: 10.1016/j.cvsm.2005.02.005