

Evaluation of the Histopathology of the Respiratory System in Essential Oil-Treated Broilers Following a Challenge With *Mycoplasma gallisepticum* and/or H9N2 Influenza Virus

Elie K. Barbour, PhD¹
Rindala G. El-Hakim, BSc¹
Marc S. Kaadi, BSc²
Hussam A. Shaib, MSc¹
Danyelle D. Gerges, BSc¹
Pia A. Nehme, MSc¹

¹Department of Animal Sciences
Faculty of Agricultural and Food Sciences
American University of Beirut
Beirut, Lebanon

²Department of Agriculture
Saint-Joseph University
Beirut, Lebanon

KEY WORDS: Avian influenza virus (H9N2), broilers, essential oils, histopathology, *Mycoplasma gallisepticum*, respiratory system

ABSTRACT

The objective of this work is to evaluate the impact of eucalyptus and peppermint essential oils (Mentofin®) in the protection of the respiratory system of broilers against controlled challenges by *Mycoplasma gallisepticum* (MG) and/or avian influenza virus H9N2. Seventy 1-day-old broilers were reared in 7 groups (10 birds/group) up to 1 week of age. Group 1 was the control (non-treated with Mentofin and unchallenged); challenged groups were Group 2 (non-treated with Mentofin and MG challenged), Group 3 (Mentofin treated and MG chal-

lenged), Group 4 (non-treated with Mentofin and H9N2 challenged), Group 5 (Mentofin treated and H9N2 challenged), Group 6 (non-treated with Mentofin and MG/H9N2 challenged), and Group 7 (Mentofin treated and MG/H9N2 challenged). At 1 week of age, an intratracheal challenge of the birds with MG (2 hemagglutination units/0.5 mL/bird) and/or H9N2 (2 hemagglutination units/0.5 mL/bird) was given to specific groups mentioned previously. Essential oils of Mentofin were administered for 6 days, effective 1 day post-challenge. Histopathological observations were concluded at 6 days post-challenge and revealed a significant reduction ($P < 0.05$) in microscopic tissue lesions of birds treated with Mentofin in comparison to birds deprived from this treatment but

challenged similarly. The significant ($P < 0.05$) reduction in microscopic lesions included a decrease in tracheal deciliation in MG- and MG/H9N2-challenged birds, a decrease in mucosal hypertrophy in MG-, H9N2-, and MG/H9N2-challenged birds, a decrease in goblet cell degeneration in MG- and MG/H9N2-challenged birds, a decrease in mucus accumulation in MG-challenged birds, and a decrease in heterophil infiltration in MG/H9N2-challenged birds.

INTRODUCTION

Mycoplasma gallisepticum (MG) is the causative agent of chronic respiratory disease in chickens,¹ a common disease in many poultry species around the world. Although the clinical manifestations are usually slow to develop, MG in combination with other respiratory pathogens can cause severe airsacculitis.^{1,2} Beside feed and egg production reduction, MG problems are of high economic significance since respiratory tract lesions can cause high morbidity, high mortality, and significant carcass condemnation and downgrading.² Consequently, the efforts to limit the losses from MG infections would be of primary importance to the poultry industry.

Avian influenza virus is one of the most devastating viral diseases in the poultry industry and has a worldwide distribution. Frequent incidences of H9N2 avian influenza type with high mortality were observed commonly on broiler farms of the Middle East region.³ Mixed infections with other respiratory pathogens, particularly MG, were incriminated resulting in high mortality on poultry farms, associated with great economic losses.³ Control of this virus would be of primary importance, especially with raising concerns of the potential of H9N2-AI to induce a pandemic spread.⁴

The essential oils of eucalyptus and peppermint present in Mentofin® have proven effective against respiratory complexes. In fact, Barbour et al 2005⁵ found that the administration of Mentofin following NDV,

IBV, and IBDV vaccination in MG/H9N2-infected broilers boosted the immune response and ameliorated their performance. Consequently, the administration of Mentofin could have similar alleviating effect on signs and lesions of MG- and/or H9N2-infected broilers.

Although several experiments were conducted to study the interaction between MG and other avian respiratory pathogens,^{6,7} no previous studies on interaction between controlled challenge by MG and/or H9N2 in poultry were done. The fact that these 2 pathogens are frequently present in the Middle East region and many other parts of the world makes the study of the effect of a controlling agent on MG/H9N2 interaction of paramount importance.

The purpose of this project is to evaluate and understand, at the cellular level, the impact of Mentofin on protection of the respiratory system of broilers against controlled challenges by MG and/or H9N2 avian influenza. The histopathological work for understanding the microscopic changes at the cellular level of the trachea included the observation of the following: tracheal deciliation, mucosal hypertrophy, goblet cell degeneration, mucus accumulation, and heterophil infiltration.

MATERIALS AND METHODS

Birds

Seventy 1-day-old broiler chicks were divided equally into 7 groups (10 chicks/group). The 7 groups were put in isolation rooms supplied with infrared lamps, waterers, and feeders. All birds were fed with the same feed as recommended previously.⁸

Preparation of Challenge Strains

MG isolate

A tracheal swab of a bird from an MG-infected flock was cultured at 37°C in Frey's broth for 4 days and subcultured onto Frey's agar for another 4 days. One MG-suspected colony with a fried egg colonial morpholo-

gy was tested against MG-specific chicken antibody (SPAFOS, Connecticut, USA). A conjugate, which is a goat anti-chicken IgG antibody (heavy + light chain), labeled with fluorescein (KPL Laboratories, Gaithersburg, Maryland, USA) was used. The reacting antibodies to the stationed fixed MG-suspected cells on a microscopic slide were observed under a fluorescent microscope (Leica DMLS, Germany) to confirm the identity of MG. The cloned-purified colony was grown in larger volume of Frey's broth for 4 days at 37°C. Pellets of MG were collected by centrifugation of the Frey's broth culture at $15557 \times g$ for 15 minutes. The MG pellets were reconstituted in 30 mL of sterile saline and the hemagglutination (HA) titer was determined against 0.1% of chicken red blood cell suspension.⁹ The reconstituted MG was further diluted to reach 2 HA units/0.5 mL of saline, an adjusted MG suspension for a challenge.

H9N2 isolate

The H9N2 strain was isolated from a severe avian influenza outbreak in broilers in the summer of 2004. The H9 component was identified at the American University of Beirut, while the complete subtyping was completed on the isolate at the Central Veterinary Laboratory of Weybridge, England. A report was issued by Dr. Ruth Manvel at Weybridge confirming the subtype as H9N2. The H9N2 was preserved at -80°C in our laboratory as 1:1 ratio of allantoic fluid:tryptose phosphate broth. This mix was diluted in sterile saline to result in 2 HA units/0.5 mL, an adjusted viral stock for a challenge.

Challenge and Treatment

The 7 groups of chicks were reared to 1 week of age. At 1 week of age, the following challenges were given as shown in Table 1. Mentofin was diluted in V/V of 0.025 mL/100 mL of drinking water. Each treated bird started receiving the diluted Mentofin, intra-esophageally, twice a day (morning and evening), in a volume of 1 mL/bird/time. The treatment was for 6 days, starting on the challenge day.

Table 1. Challenges Administered Esophageally to the Broilers at 1 Week of Age.

Groups	Challenges*	Mentofin Treatment
1	None	None
2	MG	None
3	MG	Yes [†]
4	H9N2	None
5	H9N2	Yes [†]
6	MG/H9N2	None
7	MG/H9N2	Yes [†]

*The MG and H9N2 were each given in volume of 0.5 mL intratracheally. The MG and H9N2 were each given as 2 HA units/0.5 mL/bird.

[†]Mentofin was administered on the challenge day; the administration was esophageal, twice per day (morning and evening) in a volume of 1 mL/bird/each time a day, and for a period of 6 days. The dilution of the administered Mentofin was as instructed by the manufacturer.

Histopathology

All birds were sacrificed by CO₂ asphyxiation at 6 days post-challenge. A 1-cm cross-sectional cut of each trachea from sacrificed birds was taken and kept in 10% formalin/PBS buffer. The tracheal cuts were subjected to cross-sectioning of 4 µm and H&E staining according to a previous procedure.¹⁰ The observation of tracheal deciliation, mucosal hypertrophy, goblet cell degeneration, mucus accumulation, and heterophil infiltration from 4 tracheal cuts/bird were seen microscopically at 400× within 3 fields/cut located at 4, 8, and 12 clock positions. A score of 1 was given for each of the following tracheal tissue changes, namely, deciliation, mucosal hypertrophy, goblet cell degeneration, and mucus accumulation, while a score of 0 was given to the absence of these tracheal changes. The average score of 10 birds per group was used in the histograms.

Cumulative heterophil count in 12 fields of 4 tracheal cuts/bird was recorded, and the average count of 10 birds was used in the histogram. Microscopic images, magnified 400×, were taken from selected histopathological slides to compare the tissue changes in different broiler groups.

Statistics

The mean score of the histopathological observations of the tracheal sections was done by 1-way ANOVA followed by Duncan's test, allowing for statistical comparisons among the different groups.

Animal Ethics

The Institutional Animal Care and Use Committee at the American University of Beirut abides by the interdisciplinary principles and guidelines for the use of animals in research, and this work has been approved according to such principles.

RESULTS

The histopathology of the tracheal sections uncovered the consistent significant reduction in microscopic lesions in the Mentofin-treated groups in comparison to the similarly challenged but Mentofin-deprived groups ($P < 0.05$), namely, for the microscopic lesions of tracheal deciliation, mucosal hypertrophy, goblet cell degeneration, mucus accumulation, and heterophil infiltration.

A comparison of tracheal deciliated tissue from a MG/H9N2-challenged bird deprived of Mentofin treatment in Group 6 to a normal ciliation in a similarly challenged and Mentofin-treated bird of Group 7 is shown in Figure 1. The mean scores of birds in each of the 7 groups showing deciliation are shown in Figure 2.

There was an apparent reduction in tracheal deciliation in Mentofin-treated Groups 3 and 7 in comparison to similar respective challenged Groups 2 and 6 that were deprived of Mentofin; however, the significance in this reduction at $P < 0.05$ was shown in Group 7 in comparison to Group 6, where both were challenged with MG/H9N2 organisms.

Birds of the 3 differently challenged groups showed mucosal hypertrophy on the 6th day post-challenge. Figure 3 shows a microscopic slide section of a bird's trachea from Group 6 deprived of Mentofin and challenged with MG/H9N2 in comparison to a section from the trachea of a bird from

Group 7 challenged with MG/H9N2 but treated with Mentofin. The mean scores of mucosal hypertrophy in the 7 groups of broilers are shown in Figure 4. This microscopic lesion of mucosal hypertrophy was reduced significantly ($P < 0.05$) in Mentofin-treated groups in comparison to Mentofin-deprived groups with similar challenges.

The comparison of the microscopic slide photo of a trachea with goblet cell-degeneration (bird of Group 2, MG challenged and deprived of Mentofin) versus another trachea with normal intact goblet cells (bird of Group 3, MG challenged and Mentofin treated) is shown in Figure 5. The mean scores of goblet cell degeneration among the 7 groups of broilers are shown in Figure 6. There was an apparent protection of goblet cells against degeneration by MG challenge (Group 3, Mentofin treated) and MG/H9N2 challenge (Group 7, Mentofin treated) in comparison to similarly challenged Groups 2 and 6, respectively, but deprived of Mentofin ($P < 0.05$).

Tracheal cuts with mucus accumulation versus clear tissues are shown in Figure 7. The mean scores of mucus accumulation in the tracheal sections of the 7 groups are shown in Figure 8. There was a decrease ($P > 0.05$) in mucus accumulation in tracheal sections of birds treated with Mentofin (Groups 3, 5, and 7) compared with Mentofin-deprived and respectively challenged Groups 2, 4, and 6.

Last but not least, the heterophil infiltration score was reduced significantly ($P < 0.05$) in the Mentofin-treated birds of Group 7 in comparison to Group 6 birds deprived of treatment, in which both groups had a similar challenge with MG/H9N2 (Figure 9). An insignificant reduction in tracheal heterophil occurred in birds of Group 3 (Mentofin treated, MG challenged) in comparison to those of Group 2 (Mentofin deprived, MG challenge) ($P > 0.05$). On the contrary, the heterophil score increased in Mentofin-treated birds of Group 5 (challenged with H9N2) in comparison to Mentofin-deprived birds of Group 4 (given

Figure 1. A microscope slide photograph of deciliated (Group 6, MG/H9N2 challenged and Mentofin deprived) versus normal ciliated tracheal tissue (Group 7, MG/H9N2 challenged and Mentofin treated), magnified 400x.

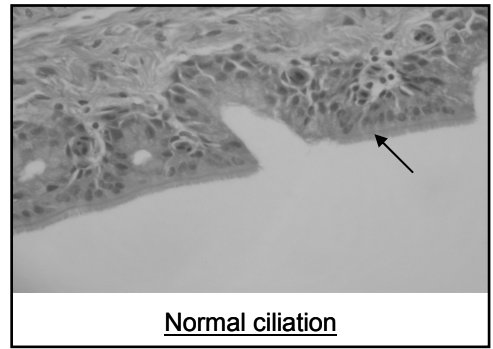
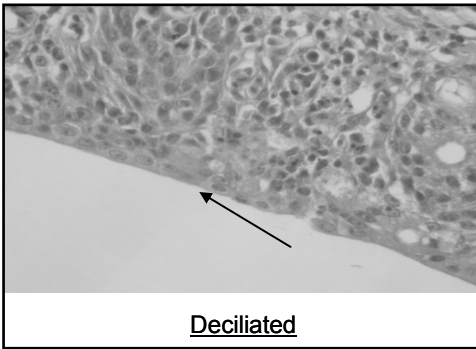
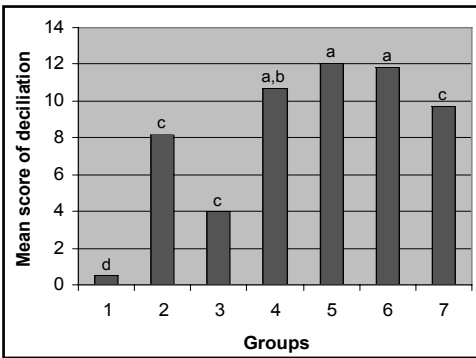


Figure 2. Mean scores of tracheal deciliation in the 7 broiler groups. Alphabets on the histogram that differ among groups are significant at $P < 0.05$.

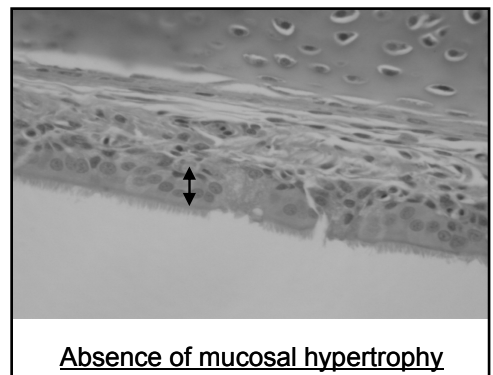
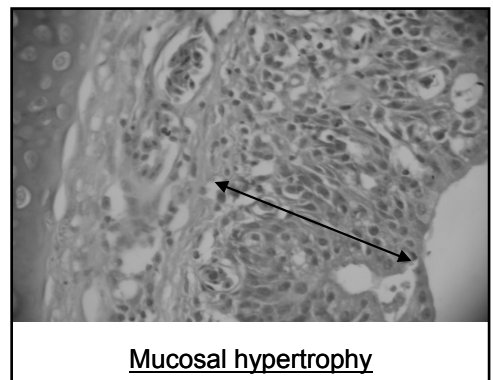


the same challenge). The microscopic slide photo in Figure 10 shows the contrast between a low heterophil infiltration in Mentofin-treated Group 7 and a high heterophil infiltration in the birds' trachea of Group 6 (deprived of Mentofin).

DISCUSSION

The reduction of deciliation by the essential oil was more apparent ($P < 0.05$) in the MG/H9N2-challenged groups. The active ingredient in Mentofin seems to protect against deciliation that is normally caused by MG and H9N2. This protection against the first line of defense in the poultry host is of paramount importance, since it will protect against colonization by secondary bacterial infections.¹¹ It is worth noting that the ciliary activity of human respiratory cells is affected by exposure to the essential oil of *Eucalyptus* spp.¹² The thinning of the mucus in

Figure 3. A microscopic slide photo of mucosal hypertrophy in a trachea from MG/H9N2-challenged bird of Group 6 (deprived of Mentofin) versus the absence of mucosal hypertrophy of a bird treated with Mentofin in Group 7 and similarly challenged, magnified 400x.



the respiratory tract by the active ingredients of *Eucalyptus* spp. could help in its outward flow, pushing with it the microorganisms, preventing their colonization, and thus protecting the cilia from consequent damage.^{13,14}

Figure 4. Mean scores of mucosal hypertrophy in the 7 broiler groups. Alphabets on the histogram that differ among groups are significant at $P < 0.05$.

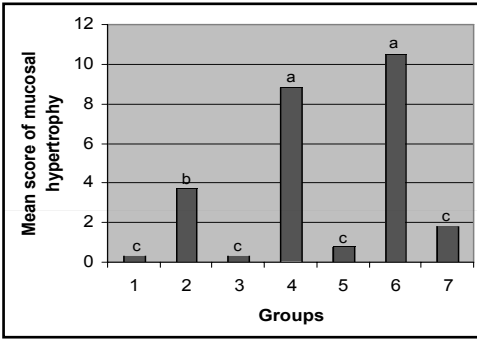


Figure 5. A microscopic slide photo of degenerated goblet cells in trachea of MG-challenged and Mentofin-deprived chicken (Group 2) versus intact goblet cells in trachea of MG-challenged and Mentofin-treated birds (Group 3), magnified 400x.

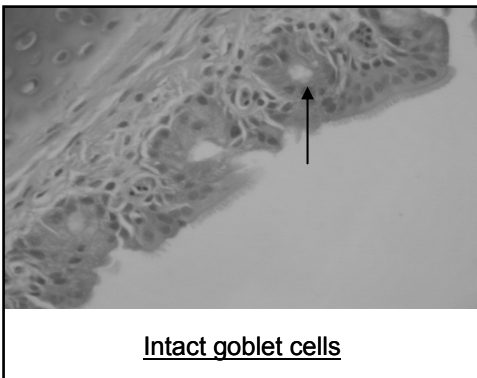
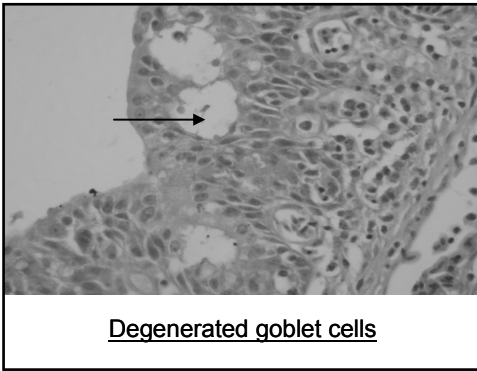


Figure 6. Mean scores of goblet cell degeneration in the 7 broiler groups. Alphabets on the histogram that differ among groups are significant at $P < 0.05$.

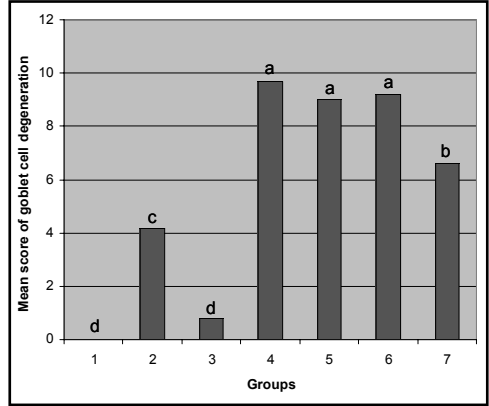


Figure 7. A microscopic slide photo of the tracheal section with mucus accumulation (Group 2, MG-challenged bird deprived of Mentofin) versus a mucus-clear tracheal section (Group 3, MG-challenged bird treated with Mentofin), magnified 400x.

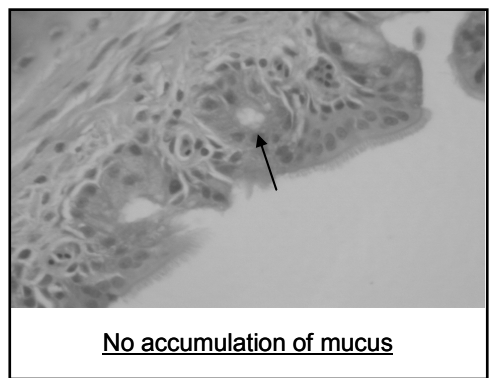
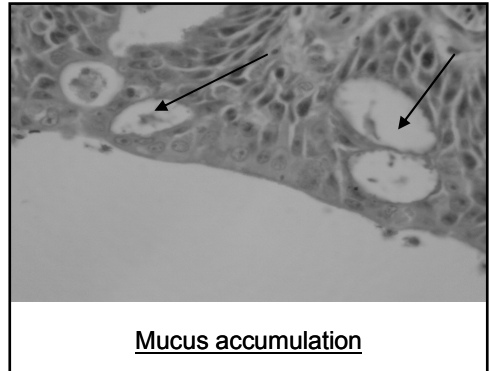


Figure 8. Mean scores of mucus accumulation in tracheal section of the 7 groups. Alphabets on the histogram that differ among groups are significant at $P < 0.05$.

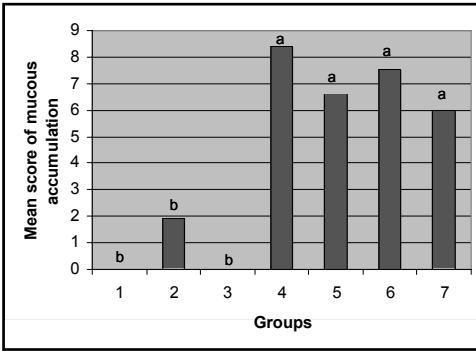


Figure 9. The mean heterophil number per 12 fields/4 tracheal cuts/bird. Alphabets on the histogram that differ among groups are significant at $P < 0.05$.

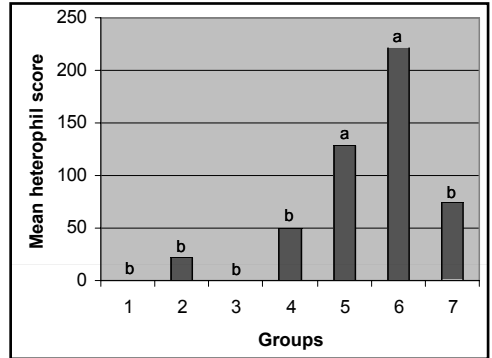
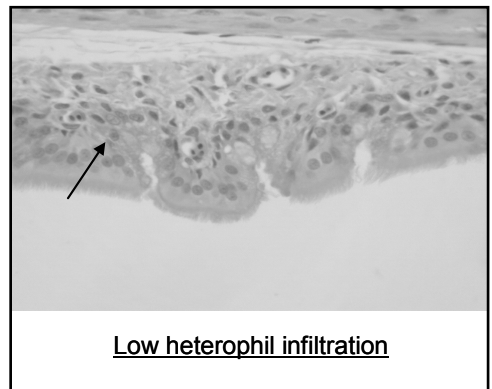
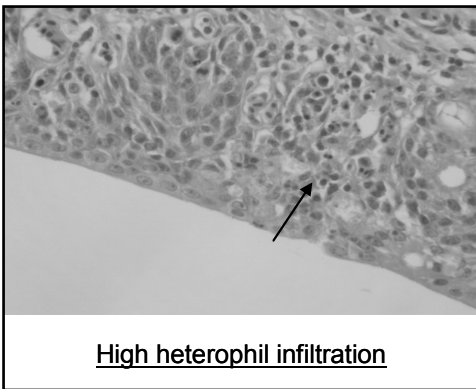


Figure 10: A microscopic slide photo of tracheal section with low heterophil infiltration (Group 7, MG/H9N2 challenged and Mentofin treated) versus high heterophil infiltration (Group 6, MG/H9N2 challenged and Mentofin deprived), magnified 400x.



Mucosal hypertrophy was significantly reduced by essential oil in birds exposed to any of the 3 different challenges ($P < 0.05$). This is a clear effect of Mentofin active ingredients on the integrity of the mucosal layer of challenged birds keeping this layer of tissue in nearness to the thickness of control birds (unchallenged, Group 1). The prevention of hypertrophy of the mucosal layer by such ingredients was documented in a previous work performed on lipopolysaccharide (LPS)-induced bronchitis in rats, proving the reduction of inflammatory cell infiltration into the epithelium of trachea and bronchioles in rats administered the essential oil of *Eucalyptus globulus*.¹⁵

Degeneration in goblet cells was reduced significantly ($P < 0.05$) by essential

oil in MG- and MG/H9N2-challenged birds. To our knowledge, there is no previous documentation on the impact of synergism among the active ingredients of *Eucalyptus* spp. and peppermint for providing protection of the goblet cells in the upper respiratory system of animal or humans. The maintenance of the goblet cell structure and function is important in respiratory diseases to keep the mucus flow in the air passages, thus pushing the germs and other particles, with the help of the maintained cilia, anteriorly and outwards through the mouth or nostrils.

The mucus accumulation was reduced significantly ($P < 0.05$) in MG-challenged birds administered the essential oil. The role of the active ingredients of Mentofin in

clearing the mucus from the tracheal tissue was reported in other works.¹³⁻¹⁸

The heterophil infiltration was reduced significantly ($P < 0.05$) by essential oil in MG/H9N2-challenged birds, while the infiltration was increased significantly by essential oil in birds challenged by H9N2 alone. This contradiction could be due to the nature of the challenge in Groups 4 and 5 that differed from those in Groups 2, 3, 6, and 7. It is worth noting that one work documented the impact of steam-distilled essential oil from *Eucalyptus globulus* on reduction of inflammatory cell infiltration and mucin hypersecretion in rats exposed to PS challenge in their respiratory system.¹⁵

In conclusion, histopathological changes were observed in Mentofin-treated versus Mentofin-deprived broilers subjected to 3 different natures of challenges (MG, H9N2, and a combination of MG/H9N2). The Mentofin treatment resulted in a significant decrease ($P < 0.05$) in tracheal deciliation in MG- and MG/H9N2-challenged birds, a significant decrease ($P < 0.05$) in tracheal goblet cells degeneration in MG- and MG/H9N2-challenged birds, a significant decrease ($P < 0.05$) in tracheal mucus accumulation in MG-challenged birds, and a significant decrease ($P < 0.05$) in heterophil infiltration in MG/H9N2-challenged birds. These results demonstrate the healing effect of Mentofin against MG/H9N2 infection, a complex respiratory disease of economic importance to the poultry industry.

REFERENCES

1. Kleven SH: Mycoplasmosis. In: Swayne DE, Glisson JR, Jackwood MW, Pearson JE, Reed WM, ed. *A Laboratory Manual for the Isolation and Identification of Avian Pathogens*. 4th ed. Kennett Square, Pa: American Association of Avian Pathologists; 1998:74-80.
2. Ley DH, Yoder HW Jr: *Mycoplasma gallisepticum* infection. In: Calnek BW, Barnes HJ, Beard CW, McDougald LR, Saif YM, eds. *Diseases of Poultry*. 10th ed. Ames, Iowa: Iowa State University Press; 1997:194-207.
3. Nili H, Asasi K: Natural cases and experimental study of H9N2 avian influenza in commercial broiler chickens of Iran. *Avian Pathol* 2002;31:247-252.
4. Chen H, Subbaro K, Swayne D, et al: Generation and evaluation of a high-growth reassortant H9N2 influenza A virus as a pandemic vaccine candidate. *Vaccine* 2003;21:1974-1979.
5. Barbour EK, Dankar, S, et al.: Essential oils of *Eucalyptus* and peppermint improve the homogeneity of immune responses and performance in MG/H9N2-infected broilers. *J Am Holistic Vet Med Assoc* 2005; 24:23-27.
6. Bradbury JM: Avian mycoplasma infection: prototype of mixed infections with mycoplasmas, bacteria and viruses. *Ann Microbiol (Institut Pasteur)* 1984;135A:83-89.
7. Corstvet RE, Sadler WW: A comparative study of single and multiple respiratory infections with *Mycoplasma gallisepticum*, Newcastle disease virus, and infectious bronchitis virus. *Am J Vet Res* 1996;27:1703-1720.
8. National Research Council. *Nutrient Requirement of Poultry*. 8th revised ed. Washington DC: National Academy Press; 1984:11-15.
9. Hierholzer JC: Adenoviruses. In: Schmidt NJ, Lennette DA, Lennette ET, Lennette EH, Emmons RW, eds. *Diagnostic Procedures for Viral, Rickettsial and Chlamydial Infections*. 7th ed. Washington, DC: American Public Health Association; 1995:169-188.
10. Randall JC, Reece LR: *Avian Histopathology*. Chicago, Ill: Mosby-Wolfe; 1966:145-170.
11. Reynolds HY: Modulating airway defenses against microbes. *Curr Opin Pulm Med* 2002;8:154-165.
12. Riechelmann H, Brommer C, Hinni M, et al: Response of human ciliated respiratory cells to a mixture of menthol, eucalyptus oil and pine needle oil. *Arzneimittelforschung*. 1997;47:1035-1039.
13. Zakay-Rones Z, Thom E, Wollan T, et al: Randomized study of the efficacy and safety of oral elderberry extract in the treatment of influenza A and B virus infections. *J Intern Med Res* 2004;32:132-140.
14. Salari MH, Amine G, Shirazi MH, et al: Antibacterial effects of *Eucalyptus globulus* leaf extract on pathogenic bacteria isolated from specimens of patients with respiratory tract disorders. *Clin Microbiol Infect* 2006;12:194-196.
15. Lu XQ, Tang FD, Wang Y, et al: Effect of *Eucalyptus globulus* oil on lipopolysaccharide-induced chronic bronchitis and mucin hypersecretion in rats. *Zhongguo Zhong Yao Za Zhi* 2004;29:168-171.
16. Wurges J: *Eucalyptus*. In: Gale Group. *Gale Encyclopedia of Alternative Medicine*. 2001. Available at: http://www.findarticles.com/p/articles/mi_g2603.
17. Gawronski DV: Medical choices. In: *Gale Group. Gale Encyclopedia of Medicine*. 2002.
18. Page L: *Healthy Healing: A Guide to Self-Healing for Everyone*. 12th ed. Sarasota FL: Bookworld Services; 2004:42-44.