

# Autologous Implant of Bone Marrow Mononuclear Cells as Treatment of Induced Equine Tendinitis

Anna Paula Balesdent Barreira, PhD<sup>1,2</sup>

Ana Liz Garcia Alves, PhD<sup>2</sup>

Mere E Saito, MD<sup>2</sup>

Renee Laufer Amorim, PhD<sup>3</sup>

Aguemi Kohayagawa, PhD<sup>3</sup>

Bruno Carvalho Menarim, DVM<sup>2</sup>

Ligia Sousa Mota, PhD<sup>2</sup>

<sup>1</sup>*Faculdade de Medicina Veterinária da Universidade Castelo Branco  
Rio de Janeiro, Brasil*

<sup>2</sup>*Departamento de Cirurgia e Anestesiologia Veterinária  
UNESP  
São Paulo, Brasil*

<sup>3</sup>*Departamento de Clínica Veterinária  
UNESP  
São Paulo, Brasil*

**KEY WORDS:** stem cell, mesenchymal cells, bone marrow, tendonitis, equine

## ABSTRACT

Superficial digital flexor tendonitis is an important cause of lameness in horses and its incidence ranges from 13% to 30%, depending on the horse's activity. This injury can occur in yearlings and compromise its carriers by reinjury or even impossibility to return to athletic life. In spite of the long period required for tendon repair, the scar tissue presents lack of elasticity and stiffness. As current treatment strategies produce only marginal results, there has been great interest in research of therapies that influence the quality or the speed of tendon repair. Stem cell therapy has shown promising results in degenerative diseases and cases of deficient healing processes. This study aims to evaluate the influence of autologous mesenchymal bone marrow stem cells in tendon healing, comparing treated and non-treated tendons. Superficial digital flexor tendonitis lesions were induced by

collagenase infiltration in both forelimbs of 6 horses, followed by autologous implant in one of the forelimbs of each animal. The horses were evaluated using clinical, ultrasonographic, histopathologic, and immunohistochemical parameters. Tendon biopsies were performed at Day 48. Results found in the treatment group, such as high inflammatory cells infiltration, extracellular matrix synthesis, reduced amount of necrosis areas, small increase in cellular proliferation (KI-67/MIB-1), and low immunoreactivity to transforming growth factor  $\beta$ 1, suggested the acceleration of tendon repair in this group. Further studies should be conducted in order to verify the influence of this treatment on later phases of tendon repair. Overall, after analysis of the results, we can conclude that cellular therapy with the mononuclear fraction of bone marrow has accelerated tendon repair at 48 days after treatment.

## INTRODUCTION

Soft tissue injuries are quite common in horses, and superficial digital flexor ten-

donitis (SDFT) is one of the most frequent causes<sup>1-6</sup> of such injuries with an incidence of 13% to 17% in racehorses<sup>6,7</sup> and 30% in hunters.<sup>8</sup>

Causes are frequently related to exercise, such as muscular fatigue, overstrain, and overheating of the tendon's core region.<sup>4,7,9</sup> However, additional factors including malformation of the limbs, improper trimming, excess weight, irregular ground surface and inadequate training can also contribute to the injury.<sup>2,10</sup>

Regardless of the cause of the injury, tendonitis can range from swelling to rupture of collagen fibers, causing hemorrhage and infiltration of macrophages, which will remove necrosis and release cytokines, especially growth factors. A chemotaxis and proliferation response from the fibroblast cells is triggered. These cells will act as or differentiate into tenocytes and synthesizing type I, III and V collagen on the scar tissue.<sup>1,6,11</sup>

Further comprehensive analyses of tendon extracellular matrix are necessary in order to provide additional information on tendon repair. Transforming growth factor  $\beta$  (TGF $\beta$ ) is an important cytokine released in tendon injury. It acts as a pro-inflammatory agent and has an expression peak at 14 days after the beginning of the lesion.<sup>12,13</sup> Immunohistochemical studies of tendon repair also allow observation of relevant characteristics, such as cell type, proliferation rate (eg, KI-67/MIB-1), and the components of the matrix.<sup>1</sup>

The use of ultrasonography has also contributed to our knowledge on the issue, providing a more accurate assessment of the degree of tendon damage and better definition of prognosis, thus permitting tests on the effectiveness of therapies for tendonitis.<sup>7,10,14</sup>

Tendon tissue naturally repairs well, but the scar tissue is functionally deficient. This has important consequences for the horse, reducing performance or even impeding the animal's return to athletic life due to re-injuries.<sup>6</sup> As related in follow-up, 70% of

Thoroughbred horses, which resume training after recovery from tendonitis, do not compete.<sup>7</sup>

Additionally the period required for recovery from tendonitis is long, ranging from 3 to 24 months depending on the lesion. During this period, the animal should follow a rehabilitation program whose purpose is to minimize loss of tendon elasticity and thus reduce re-injury.<sup>2</sup>

Notwithstanding the wide range of studies about tendonitis, the currently treatments used for this condition show limited benefits. Despite of the positive antiinflammatory effects, there are so far no drugs that optimize the quality of tendon repair or reduce the healing period. For this reason, conventional tendonitis therapy has been frustrating veterinarians all over the world.

In spite of previous knowledge concerning the existence of stem cells, which usually take part in tissue growth, repair, and remodeling, new research has been conducted to identify and study these cell populations' control mechanisms.<sup>15,16</sup> Since the discovery of the differentiation potential of stem cells, their therapeutic applications have been explored, whether as cell implants or in bioengineering for transplants. The exact mechanism adopted by the implanted cells is not known yet, but the hypothesis is that the cells would stimulate tissue repair by providing the cellular elements required during the process and guaranteeing a new generation of cells or even differentiating into matures cells from the damaged tissue.<sup>17</sup> The production of supramolecular structures such as extracellular matrix is also necessary to provide a fully functional space organization for the tissues and their systemic integration.<sup>18</sup>

Regenerative medicine has been tested on equine tendonitis and desmitis by researchers.<sup>6,18-20</sup> There are several sources of stem cells in adult animals, one of which is bone marrow.<sup>21</sup> In horses, it can be harvested by sternum bone aspiration.<sup>16,19,22</sup> For treatment of tendonitis, a bone marrow sample can be implanted as total bone marrow, a

mononuclear fraction, or even mesenchymal stem cells expanded *in vitro*. The possibility exists to harvest mesenchymal stem cells from adipose tissue, assuming that adipocytes would differentiate into fibroblasts and then into specialized cells (tenocytes), according to exogenous stimulation.<sup>23</sup>

The purpose of this study was to check the feasibility of bone marrow aspiration puncture, performed on standing horses and mainly to verify the effectiveness of autologous implant of mononuclear fraction cells, including mesenchymal stem cells, in the treatment of tendonitis.

## MATERIALS AND METHODS

Six equines were used, 3 females and 3 males, of mixed breed, aged between 2 and 12 years, clinically healthy, without soundness problems and kept at the Veterinary Hospital of the Veterinary and Zootechny School of The University of the State of São Paulo (Hospital Veterinário da Faculdade de Medicina Veterinária e Zootecnia da UNESP), in Botucatu, Brazil.

This protocol was performed with permission from UNESP Animal Ethics Committee, protocol number 16/2003 (Câmara de Ética em Experimentação Animal, FMVZ, Botucatu).

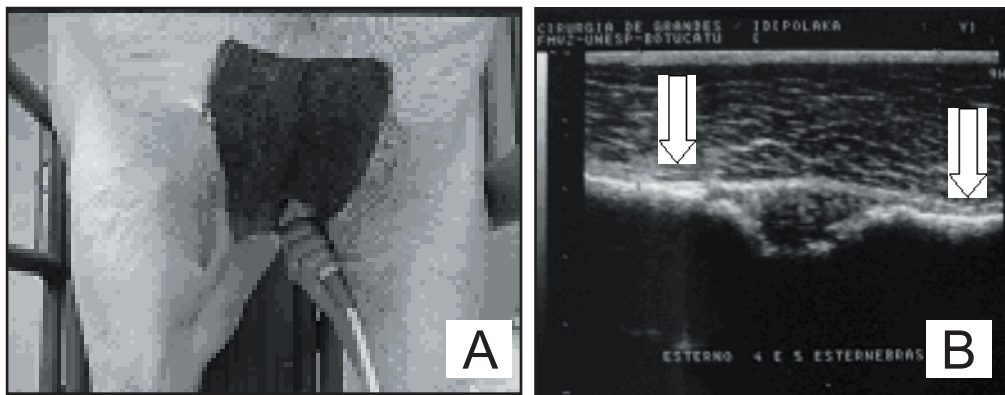
At Day 0 of the experiment, SDFT lesions were induced on both forelimbs of the animals through intratendon injection of collagenase (collagenase type 1: C-0130, Sigma Pharmaceutical), guided by ultrasound. The

injured tendons were randomly distributed into 2 groups: GA (treatment group) and GB (control group). At Day 12 of the experiment, GA received implants of mononuclear fraction cells, mesenchymal cells included, while GB received no implant. The animals were confined for 2 weeks in individual stalls and, after this period, were submitted to a progressive physical activity program. Clinical and ultrasound monitoring was performed from Day 0 to Day 48, when a biopsy was carried out for examination of histopathological and immunohistochemical characteristics. All the examiners were blinded to the samples, except the ultrasonographer. For this reason, subjective analyses were evaluated by two examiners, as the echo pattern of the lesion.

Administration of collagenase (1.0 mL, 2.5 mg/mL) was performed after sedation with an intravenous application of romifidine (Sedivet, Boehringer; 40 mcg/kg P.V.) and anesthetic blocking of the medial and lateral palmar nerves. For ethical reasons, after induction of the lesion, Meloxicam, a non-steroidal antiinflammatory drug, was administered orally at 0.6 mg/kg, once a day for 15 days.

To harvest the bone marrow, the animals were standing in stocks and sedated with romifidine. The 5th sternebra was located with an ultrasound guide (Figure 1). After local anesthetic blocking, antisepsis was performed and a Jamshidi needle (Technology, SP; 8 G and 12 cm) was introduced.

**Figure 1.** Ultrasound examination of the sternum bone region. A: Scan. B: Sonographic image of the 4th and 5th sternebrae (arrows).



Bone marrow was aspirated using syringes containing sodium heparin (5000 UI). The samples were identified and transferred into sterile tubes and placed on ice for immediate transfer to the Cytogenetic Laboratory of the Biosciences Institute of the São Paulo State University.

Besides macroscopic observation of spikes on Petri dishes, slides were taken, which, through Romanowsky staining, allowed confirmation of the source of the sample, whether bone marrow or peripheral blood. All laboratory manipulation was carried out in laminar flow to prevent contamination of the sample.

Once bone marrow source was confirmed, the sample was diluted in PBS and filtered through a transfusion set (Embramed, SP) to remove cell aggregates. After that, the filtered material was delicately deposited in Ficoll Hypaque (Ficoll-Paque Plus [d=1,077], Sigma Chemical Co.) and separate through density centrifugation, forming a whitish ring rich in mononuclear fraction of bone marrow. This layer was washed until it was ready to be submitted to the cell viability test, through exclusion of trypan blue 0.2%.

Twelve days after collagenase application, a SDFT from one of the forelimbs was randomly seeded with intratendon mononuclear cells, forming the treatment group. The tendons of the control group did not receive any intervention on this date. The implant was performed while the animal was under sedation and regional blocking, as described before. The injured area was identified by ultrasound, then antisepsis was carried out and an intralesional implant of approximately 0.5 mL of cell suspension diluted in freshly obtained autologous serum was performed (Figure 2).

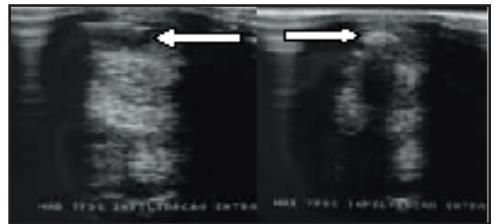
The animals were submitted to progressive physical activity, following the Gillis system<sup>2</sup> modified and monitored by ultrasound examination. They were monitored for 48 days, from induction of the lesion to tendon biopsy. During the first 15 days, daily clinical examinations were conducted

from a blinded group. When the influence of lameness in the forelimbs made analysis difficult, anesthetic blocking of the contralateral limb was performed. The presence of lameness was reported and rated from 1 to 4 according to Stashak,<sup>24</sup> as well as any swelling, temperature and pain on digital pressure:

- 1 = lameness is not observed at walk, but is recognized at trot
- 2 = an alteration in gait is noted at walk, but no overt head movements are associated with it
- 3 = lameness is obvious at both a walk and trot
- 4 = a non weight-bearing lameness is present

Any increase in volume, temperature and pain on palpation was also noted. After the first 15 days, examinations were performed every 12 days and classified according to an intensity score, considering (1) light; (2) mild; and (3) severe.

**Figure 2.** Ultrasound guided cell implant. A: Ultrasound image of needle in lesion (arrow). B: Implanted cells (arrow).



The ultrasound exam was conducted using portable equipment (ALOKA, Model SSD 900), with a linear 7.5 MHz transducer, for monitoring the tendons at Days 2, 12, 24, 36, and 48 of the experiment. The tendon area was evaluated, as well as the area and echogenicity of the lesion, rated from 1 to 4, in accordance with Genovese et al.<sup>25</sup>

- 1 = slightly (25%) less echogenic than normal
- 2 = half echogenic and half anechoic
- 3 = mostly anechoic (75%)
- 4 = completely anechoic

Given that this is a non-parametric analysis, the images were evaluated by 2 different ultrasonographers and then the results were compared and a mean classification

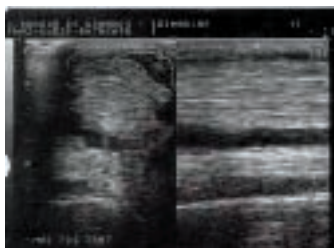
adopted. Finally the percentage of injured area within each tendon was calculated (Figure 3).

The animals were submitted to general anesthesia at Day 48 for SDFT biopsy of both forelimbs, the lesion was located, and a 1 cm<sup>2</sup> fragment was obtained. After fixation with tamponade formalin (10%), the fragments were taken to the Veterinary Pathology Service of School of Veterinary Medicine and Animal Science, São Paulo State University UNESP. They were processed through the usual methods for paraffin embedded tissue, 3 μm sections were stained with hematoxylin and eosin and 2 new slides were made for immunohistochemical technique. Histopathological analysis was performed from a blinded examiner with optical microscopes, considering the amount and characteristics of the fibroblasts, the presence and type of inflammatory infiltrate, neovascularization, collagen fibers, appearance of the extracellular matrix, and the tissue disorganization rate. The score system used for grading was the following:

- 1 = light (up to 25% of the field in high grade [400×] magnification)
- 2 = mild (from 25% to 50%)
- 3 = severe (more than 50%)

For the immunohistochemical technique, the sections were deparaffined, dehydrated, and submitted to antigen retrieval in a pre-heated Citrate Buffer 10 mM, pH 6.0 in a water bath at 96°C, for 25 minutes. For incubation, MIB-1 primary antibody (DAKO, Clone MIB-1) and TGFβ lyophilized monoclonal antibody (NCL, TGFβ

**Figure 3.** Ultrasound image of treatment group core lesion (type II), with 27% of fibers compromised in cross sectional view (left) and longitudinal view (right).



monoclonal) type 1 were used. The primary antibodies were incubated overnight at 4°C and later with a labeled streptavidin biotin complex (LSAB, DAKO), according to the manufacturer's instructions. The material was incubated with streptavidin-peroxidase at room temperature for 30 minutes, and diaminobenzidine was used as a chromogen for 5 minutes. Counter-staining was performed with hematoxylin, after which the cells that were marked positive for TGFβ1 and KI-67/MIB-1, cytoplasm, and nucleus markers, respectively, were counted.

Non-parametric Friedman and Wilcoxon tests were used to analyze the results expressed in scores. For parametric data, a repeated measure analysis was used, in addition to a paired *t*-test, all with 5% significance level.<sup>26</sup>

## RESULTS AND DISCUSSION

We observed that the technique for equine bone marrow aspiration, while the horses are in quadrupedal position and sedated, as described by Speirs<sup>22</sup> and Smith et al<sup>16</sup> is feasible, despite the discomfort caused to the person collecting the sample due to the position relative to the animal and the ventral dorsal force needed for penetration of the needle. This result is shown to be relevant when cost and risk reduction are considered, compared to the technique described by Herthel<sup>21</sup> and Thomas,<sup>19</sup> in which the animals are placed in dorsal recumbency and under general anesthesia.

The macroscopic appearance of bone marrow samples was similar to that described by Car and Blue<sup>27</sup> and was characterized by blood containing droplets of fat and small gray granules. However, no descriptions were found in the related literature concerning the gel-like consistency of the sample, especially the first aliquot, and its persistence in forming small cell aggregates, even with the use of anticlotting agents.

In spite of the size of the needle and of its deep penetration into the bone tissue, pain was not observed, therefore suggesting the effectiveness of anesthetic blocking coupled with sedation. Nevertheless,

appropriate pain evaluation would require monitoring of other parameters.

The procedure for mononuclear separation using the described technique was shown to be feasible. This is compatible with the results obtained by Perin et al,<sup>28</sup> who describe a similar procedure on humans. However, a difference was found to the viability of the sample: 76% was obtained in the current research, and 96% in Perin's paper. Other published research on equines did not perform this procedure.<sup>18,21,24</sup> The difference in results between humans and equines indicates the need for adjusting the procedure to the species in future trials. It is possible that use of refrigerated centrifuging equipment may reduce cellular death, since the procedure requires up to 30 minutes of centrifugation, resulting in heating of the equipment and of the sample. We believe this cellular viability test to be important prior to the implant, so as to ensure the reliability of the implant.

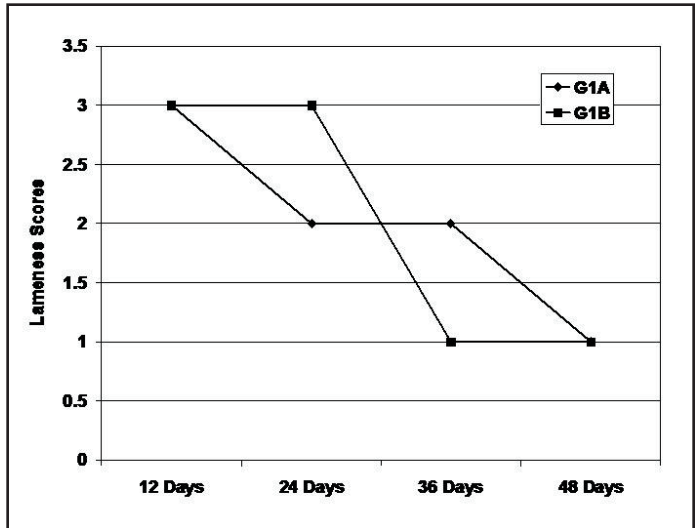
In agreement with the literature,<sup>14,19,22</sup> we can state that tendonitis induced by administration of 1.0 mL (2.5 mg/mL) of collagenase has been demonstrated to be an efficient model for studying tendon repair. The increase in the tendon area after administration of collagenase was interpreted as an edema due to the inflammation process, which was present until Day 30 on all animals, and until the end of the experiment on only one animal. This is consistent with reports by Williams<sup>29</sup> and Gift et al.<sup>30</sup> The lameness evaluation was variable, but on average was graded as 3 at the beginning and as 1 at the end of the experiment, as shown in Figure 4.

Also consistent with the published literature, the cell implant was shown to be a simple technique when guided by ultrasound.<sup>1,14,31</sup> After the implant, the clinical signs of local inflammation were observed

to be stronger for an average of 3 days, displaying a difference from therapeutic intralesional infiltration (Glycosaminoglycan or Beta-aminopropionitrile fumarate), in which swelling or pain on digital pressure of the tendon are not observed, as described by Reef.<sup>10</sup>

The ultrasound images of the lesions induced within this experiment made it possible to identify their borders. This result is in accordance with the findings of some authors,<sup>14,25,32</sup> but different from those others<sup>30</sup> who did not obtain a clear image even 1 week after the start of the lesion. The lesions induced by collagenase were found to compromise up to 42.5% of the fibers in the cross section of the control group and up to 39.6% in the treatment group (Figure 5), presenting grade 2.5 as maximum average echogenicity in both groups.

**Figure 4.** Mean of lameness scores from experimental groups in the different analyzed moments.



In this study, we observed that the difference between groups was greater at the end, when compared with the beginning of the experiment. This result points to a higher intensity in repair activity in the treatment than controlled group.

The chief findings in the histopathological analysis of both groups were related to initial phases of inflammation and tendon repair events. Vascular changes (hemor-

rhaging and edema) and necrosis areas were observed in the acute phase, while mononuclear infiltrates, fibroblasts proliferation, and intensification of the extracellular matrix were observed in the subacute phase (Figure 6). Differences were observed between the groups. Of these differences, the findings in the acute phase of the control group and in the subacute phase of the treatment group are predominant. The histopathological changes found on Day 48 after the lesion are not in accordance with the chronology reported by some authors,<sup>33,34</sup> where the predominance of hemorrhage, edema, and necrosis are mentioned only during the first week of tendon repair in horses. In the present experiment, these alterations were still present on the 48th day, especially in the control group animals.

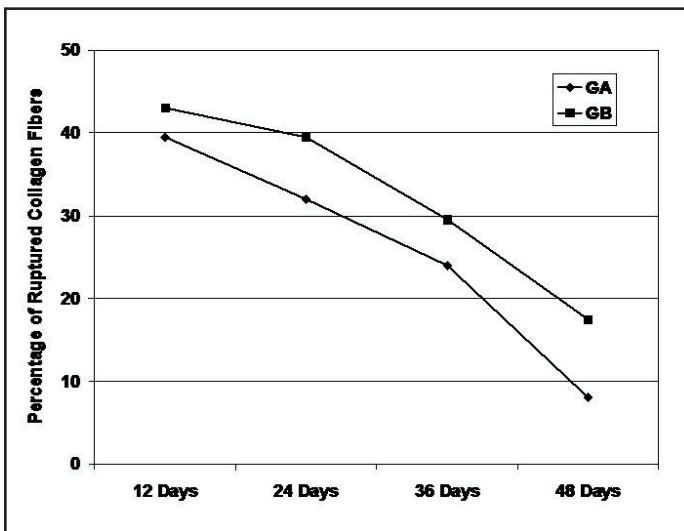
In the immunohistochemical evaluation, the TGFβ1 antibody was tested positive in the activated fibroblasts, with significant difference between the groups. The control group presented reactivity of 30% and the treatment group presented 15.5% reactivity, which indicates higher intensity of TGFβ1 released in the control group (Figure 7). Considering that this cytokine is abundant in the exudation and acute phase of the tendon inflammation process, the finding is

consistent with histopathological results, in which the treatment group is shown to be in a subacute phase and the control group in an acute phase.

The purpose of using KI-67/MIB-1 as a cell proliferation marker was to detect events from the subsequent phase associated to TGFβ1, when the fibroblasts start proliferating and differentiating into tenocytes to perform the synthesis of the extracellular matrix.<sup>1</sup> As to the results related to this rate, no significant difference was observed between the groups (8.1% in the treatment group and 7.4% in the control group). Nevertheless, when analyzing the data without including one animal that revealed clinical, ultrasonographic, and histopathological signs of the lesion having returned to an acute stage, thus deviating the average of the control group proliferation rate, we obtained a significant difference between the groups (8.1% in the treatment group and 4.2% in the control group) ( $P < 0.05$ ).

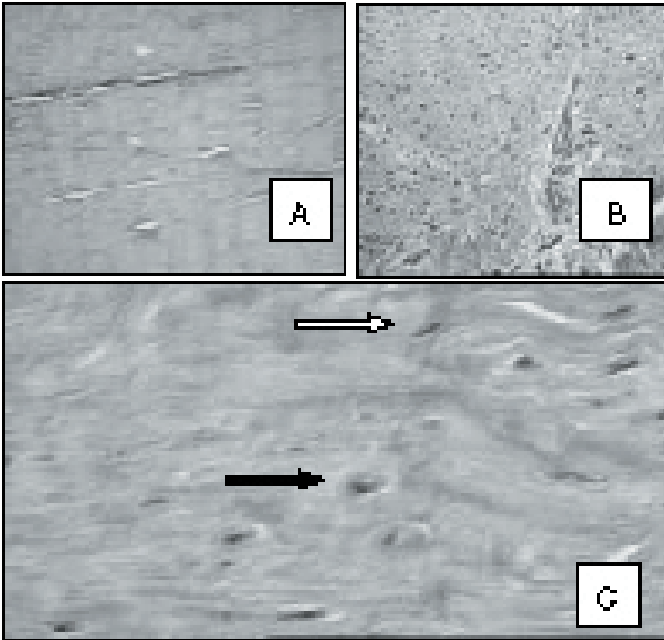
The histopathological and immunohistochemical results obtained in this study showed that the groups presented differences related to the tendon repair phase and that there was a predominance of acute inflammation phase events in the control group and subacute phase events in the treatment

**Figure 5.** Mean values of the percentage of ruptured collagen fibers in a cross-sectional view from the experimental groups in the different analyzed moments.




group. Therefore, we can consider, based on ultrasonographic, histopathological, and immunohistochemical analysis, that the effect of the treatment with cells from the mononuclear fraction of the bone marrow applied to tendon lesions induced in this experiment has accelerated tendon repair. This consideration is in accordance with data by Herthel<sup>21</sup> and Thomas,<sup>19</sup> who suggested the same effect, but based only on clinical, ultrasonographic, and functional analysis.

**Figure 6.** Tendon histopathology. A: Normal tendon with aligned collagen fibers and few tenocytes, hematoxylin and eosin, 200 $\times$ . B: Control group tendon – collagen fiber disorganization, hematoxylin and eosin, 200 $\times$ . C: Treated group tendon – presence of fibroblasts (white arrow) and round undifferentiated cells (black arrow), hematoxylin and eosin, 400 $\times$ .



**Figure 7.** Cytoplasmatic immunomarking for TGF $\beta$ 1. Treated group (A) presents lower immunomarking rate compared with the control group (B).



As a result, we believe that the use of cellular therapy, combined with a controlled physical activity program, can accelerate the tendon repair process and contribute decisively to reduce the recovery period. Further studies must be conducted to add information about the ideal protocol and selective clinical cases for this technique.

## REFERENCES

1. Dahlgren LA, Nixon AJ, Brower-Toland BD: Effect of beta-aminopropionitrile on equine tendon metabolism in vitro and on effects of insulin-like growth factor-I on matrix production by equine tenocytes. *Am J Vet Res* 2001;62:1557-1562.
2. Gillis CL: Tendon and ligament rehabilitation. *Proceedings of the Dubai International Equine Symposium*. Dubai: Neyenesch Printers; 1996:417-422.
3. Goodship AE, Birch HL, Wilson AM: The pathology and repair of tendon and ligament injury. *Vet Clin North Am Equine Pract* 1994;10:323-349.
4. Patterson-Kane JC, Wilson AM, Firth EC, Parry DAD, Goodship AE: Exercise-related alterations in crimp morphology in the central regions of superficial digital flexor tendons from young Thoroughbreds: a controlled study. *Equine Vet J* 1998;30:61-64.
5. Rantanen NW, Hauser ML, Genovese RL: Superficial digital flexor tendinitis: diagnosis using real-time ultrasound imaging. *J Equine Vet Sci* 1985;5:115-119.
6. Richardson LE: The use of mesenchymal stem cells in the treatment of equine tendon injuries. Department of Veterinary Clinical Sciences, The Royal Veterinary College, 2005.
7. Oikawa M, Kasashima Y: The Japanese experience with tendonitis in racehorses. *J Equine Sci* 2002;13:41-56.
8. Goodship AE, Birch HL: The pathophysiology of the flexor tendon in the equine athlete. *Proceedings of the Dubai International Equine Symposium*. Dubai: Neyenesch Printers; 1996:83-108.
9. Patterson-Kane JC, Wilson AM, Firth EC, Parry DAD, Goodship AE: Comparison of collagen fibril populations in the superficial digital flexor tendons of exercised and no exercised Thoroughbreds. *Equine Vet J* 1997;29:121-125.
10. Reef VB: *Equine Diagnostic Ultrasound*. Pennsylvania: W.B. Saunders Company; 1998.



11. Alberts B, Johnson A, Lewis J, Raff M, Roberts K, Walter P: *Biologia Molecular da Célula*. 4th ed. Porto Alegre: Artmed; 2004.
12. Chang J: Gene expression of transforming growth factor beta-1 in rabbit zone II flexor tendon wound healing: evidence for dual mechanisms of repair. *Plast Reconstr Surg Baltimore* 1997;100:937-944.
13. Ngo MBS: Gene expression of transforming growth factor beta-1 in rabbit zone II flexor tendon wound healing: evidence for dual mechanisms of repair. *Plast Reconstr Surg Baltimore* 1997;100:1260-1267.
14. Alves ALG, Rodrigues MAM, Aguiar AJA, et al: Effects of beta-aminopropionitrile fumarate and exercise on equine tendon healing: gross and histological aspects. *J Equine Vet Sci* 2001;21:335-340.
15. Richardson LE, Dudhia J, Clegg PD, Smith R: Stem cells in veterinary medicine—attempts at a regenerating equine tendon after injury. *Trends Biotechnol* 2007;25:409-416.
16. Smith RKW, Korda M, Blunn GW, Goodship AE: Isolation and implantation of autologous equine mesenchymal stem cells from bone marrow into the superficial digital flexor tendon as a potential novel treatment. *Equine Vet J* 2003;35:99-102.
17. Levenberg S, Huang NF, Rogers AB, Itskovitz-Eldor J, Langer R: Differentiation of human embryonic stem cells on three-dimensional polymer scaffolds. *Proc Nat Acad Sci USA* 2003;100:12741-12746.
18. Smith RKW, Webbon PM: The physiology of normal tendon and ligament. *Proceedings of the Dubai International Equine Symposium*. Dubai: Neyenesch Printers; 1996:55-81.
19. Thomas HS: Mending with marrow. *Horse* 2003;53-56.
20. Young RG, Butler DL, Weber W, Caplan AI, Gordon SL, Fink DJ: Use of mesenchymal stem cells in a collagen matrix for Achilles tendon repair. *J Orthop Res* 1998;16:406-413.
21. Herthel DJ: Suspensory desmitis therapies equine. *Proceedings of the AC Veterinary Symposium*. San Diego; 2002:165-167.
22. Speirs VC: Exame clínico de eqüinos. Porto Alegre: Artmed; 1999:319-321.
23. Zuk PA, Zuh M, Ashjian P: Human adipose tissue is a source of multipotent stem cells. *Mol Biol Cell* 2002;13:4279-4295.
24. Stashak TS: *Adam's Lameness in Horses*. 4th ed Philadelphia: Lea & Febiger; 2002:4449.
25. Genovese RL, Rantanen NW, Hauser ML, Simpson BS: Diagnostic ultrasonography of equine limbs. *Vet Clin North Am Equine Pract* 1986;2:145-226.
26. Zar JH: *Biostatistical Analysis*. Upper Saddle River, NJ: Prentice Hall; 1996:718.
27. Car BD, Blue JT: Punção aspirativa e biópsia de medulla óssea. In: Feldman BF, Zinkl JG, Jain NC, eds. *Shalm's Veterinary Hematology*. Philadelphia: Lippincott Williams and Wilkins; 2000:18-29.
28. Perin EC, Dohman FR, Borojevic R, et al: Transendocardial, autologous bone marrow cell transplantation for severe, chronic ischemic heart failure *Circulation* 2003;107:2294-2302.
29. Williams IF: Studies on the pathogenesis of equine tendonitis following collagenase injury. *Res Vet Sci* 1984;36:326-328.
30. Gift LJ, Gaughan RM, DeBowes JP, et al: The Influence of intratendinous sodium hyaluronate on tendon healing in horses. *Vet Comp Orthop Traumatol* 1992;5:151-157.
31. Gaughan EM, DeBowes RM, Gift LJ: Medical Management of Flexor Tendon Disorders in Horses. *Equine Diagnostic Ultrasound*. 1st ed. Baltimore: William and Wilkins; 1998:572-576.
32. Denoix J: Functional anatomy of tendons and ligaments in the distal limbs (manus and pes). *Proceedings of the Dubai International Equine Symposium*. Dubai: Neyenesch Printers; 1996:23-54.
33. Davis WM: The clinical application of scar remodeling in disease status. *Proceedings of the Dubai International Equine Symposium*. Dubai: Neyenesch Printers; 1996:407-416.
34. Pool RR: Pathologic changes in tendinitis of athletic horses. *Proceedings of the Dubai International Equine Symposium*. Dubai: Neyenesch Printers; 1996:109-117.